

## *Streptococcus pneumoniae* endocarditis in a child: a case report

### Endocarditis por streptococcus pneumoniae en pediatría. Presentación de un caso clínico

Florencia Escarrá<sup>a</sup>, Ana G. Fedullo<sup>a</sup>, Natalia Veliz<sup>b</sup>, Julián Rosa<sup>b</sup>,  
Rodrigo Oribe<sup>c</sup>, Marisa Di Santo<sup>c</sup>, Bqca. Vanesa Reijtman<sup>d</sup>,  
Lic. Alejandra Mastroianni<sup>d</sup>, Guadalupe Pérez<sup>a</sup>

<sup>a</sup>Infectious disease department. JP Garrahan National Pediatric Hospital, Buenos Aires, Argentina.

<sup>b</sup>Internal medicine department. JP Garrahan National Pediatric Hospital, Buenos Aires, Argentina.

<sup>c</sup>Cardiology department. JP Garrahan National Pediatric Hospital, Buenos Aires, Argentina.

<sup>d</sup>Microbiology department. JP Garrahan National Pediatric Hospital, Buenos Aires, Argentina

Fecha recibido: 07-02-2017; Fecha aceptado: 01-07-2017

#### Abstract

**Introduction:** the incidence of invasive infections caused by pneumococcus (*Streptococcus pneumoniae*) has declined since generalized vaccination with pneumococcal conjugated vaccine, but it is still a prevalent pathogen in children. Amongst pneumococcal invasive infections, IE (infectious endocarditis) is rare, with an incidence between 1 and 7%. **Case report:** We describe the case of a previously healthy 4 year old boy, who had received one dose of 10-valent pneumococcal conjugate vaccine who presents with fever, a new heart murmur and heart failure. Blood cultures were positive for penicillin susceptible pneumococcus. The transthoracic echocardiogram showed tricuspid and pulmonary valve vegetations. The patient received 4 weeks of antibiotic treatment for pneumococcal IE. He presented secondary valve damage that needed surgical treatment. **Conclusions:** IE should be considered as a differential diagnosis of children presenting with fever and a newly diagnosed heart murmur, and pneumococcus as an etiologic agent in non hospitalized febrile patients with severe infections.

#### Keywords:

Endocarditis;  
*Streptococcus pneumoniae*,  
child, bacterial  
infections

## Introduction

Pneumococcal infections have decreased in the last decade due to the use of the pneumococcal conjugate vaccine around the world. However, they are still prevalent in pediatrics. Infectious endocarditis (IE) caused by *S pneumoniae* is a rare form of presentation<sup>1</sup>. In the pre-antibiotic era, pneumococcus caused between 10 and 15 percent of IE<sup>2</sup>. Nowadays, the reported incidence ranges from 1 to 7 percent<sup>3,4</sup> probably related to the early antibiotic treatment of respiratory tract infections and bacteremias, and pneumococcal vaccine<sup>5</sup>.

IE is a disease with high morbidity and mortality and it requires a high index of suspicion since the identification of the germ and the endocardial compromise, the early treatment, and avoiding possible complications, are decisive factors in the outcome of the patient.

The objective is to present the case of a child with no history of disease, who was admitted with pneumococcal IE.

## Clinical Case

A 4-year-old child, born in Paraguay and without previous pediatric controls, was referred to J. P. Garrahan Hospital with a clinical history of fever of 10 days of evolution, and heart failure. The patient had no clinical history of disease, and the national schedule immunization program had been applied, with a dose of 10-valent pneumococcal conjugate vaccine after 12 months of age according to the protocol used in Paraguay.

The patient had consulted in place of origin for 10 days of fever, asthenia and adynamia. A physical examination showed sustained tachycardia and an intermittent third heart sound.

The child was referred with a diagnosis of heart failure for a reassessment of probable undiagnosed congenital heart disease. At the time of admission, the patient was severely ill, fever 104°F (40 °C), pallor of skin and mucous, normotensive (85/60 mmHg), and tachycardic (120 beats/min). A systolic heart murmur in pulmonary focus and another in mesocardial area were found, with dorsal irradiation and to all foci, both of 4/6 intensity. The splenic edge was found 2 cm below the left costal arch and he presented mild painful hepatomegaly.

An ECG (electrocardiogram) showed sinus rhythm, atrioventricular conduction 1 to 1, heart rate 110 beats/min, P-R interval 0.12 msec. QRS axis 60°. Deep Q wave in Lead III only. Signs of septal and right

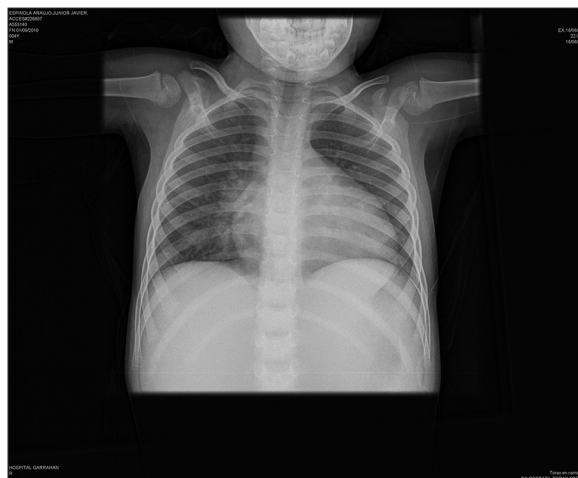
ventricle hypertrophy. Nonspecific repolarization disorder (inverted T wave in V5).

The chest X-ray showed cardiomegaly (cardiothoracic ratio 0.65). Figure 1.

In the first laboratory tests, the patient presented hyperleukocytosis with left deviation (28,700 white blood cells/mm<sup>3</sup>, 79% neutrophils, 13% lymphocytes) and anemia (Hb 10.7 gr%) with thrombocytosis (450,000 platelets/mm<sup>3</sup>). The erythrocyte sedimentation rate in the first hour was higher than 120 mm and the C-reactive protein was increased (292 mg/L, normal value up to 5 mg/L). A TTE (transthoracic echocardiogram) was performed and it showed a 1 cm rounded image on the auricular surface of TV (tricuspid valve) with tricuspid insufficiency due to septal perforations and other images in PV (pulmonary valve), the greatest of 5 mm. In addition, a RV (right ventricle) hypertrophy was observed with outflow tract obstruction and subtricuspid IVC (interventricular communication). The ventricular function was normal. The IVC was read as secondary since in the retrospective review of the echocardiogram performed in the beginning of the clinical picture in the place of origin an interventricular shunt had not been evidenced and, instead, a vegetation was observed in that localization.

The day of the hospital admission, 3 peripheral BC (blood cultures) were performed and intravenous antibiotic treatment was indicated with vancomycin 60 mg/kg/day every 6 hours, gentamicin 5 mg/kg/day every 8 hours, and ceftriaxone 100 mg/kg/day with a diagnosis of native valve IE.

On the second day of hospitalization, 2/3 BC from bottles incubated in automated system BacT/ALERT® (bioMérieux) develop pneumococcus. It was presumptively categorized with optochin sensitivity and it was confirmed by bile solubility test and by mass spectro-



**Figure 1.** Chest X-ray on the day of admission: evidence of increased cardiothoracic ratio (0.65).

metry with VITEK® MS (bioMérieux) with a level of confidence of 99.9%. The sensitivity tests were performed according to CLSI current guidelines<sup>6</sup>. It was sensitive to penicillin with a MIC of 0.04 ug/ml and ceftriaxone with a MIC of 0.04 ug/ml. The strain was referred to the national reference laboratory National Laboratories and Health Institutes Administration Carlos G. Malbrán (ANLIS) where it was serotyped using the *Quellung* reaction. Its capsular serotype was 6A.

From the microbiological identification, the antibiotic treatment was modified to ceftriaxone 80 mg/kg/day.

The general condition of the patient improved. After 72 hours of proper treatment, the BC were negatives. One week after hospitalization, the child was still febrile. The control echocardiogram showed the disappearance of one of the vegetations described on the PV and the concomitant appearance of pleural effusion was documented. Thoracocentesis and pleural tube insertion were performed. The pleural fluid culture was negative.

The child was febrile until day 11 of treatment. The acute-phase proteins slowly improved during hospitalization.

He completed 4 weeks of intravenous treatment and was discharged from the hospital with acute-phase reactants within normal ranges. The last echocardiogram showed severe TV insufficiency with small pulmonary vegetation and subtricuspid IVC with left-right shunt. One month after discharge, valvuloplasty of the TV was performed, as well as the surgical correction of residual IVC. The culture of the excised vegetation was negative.

The patient received a 13-valent pneumococcal conjugate vaccine for residual heart disease. Antibiotic prophylactic measures were indicated for IE. The child continues under pediatric, infectious and cardiological follow-up with excellent evolution.

## Discussion

IE in children is a rare disease but it generates high morbidity and mortality. In children, the true incidence of IE is not known because there are few reported series. In Argentina, at J. P. Garrahan Hospital in 2007, the estimated incidence of IE was 4.9/10,000 admissions/year<sup>1</sup>.

The pediatric epidemiology of IE has changed radically in the last decades. In the past, the main predisposing factor was rheumatic heart disease. However, currently, 80-90% of patients have other underlying conditions, the most important being congenital heart disease with or without previous surgery.

The etiological agents of native valve IE in children are mainly *S aureus*, bacteria of the genus *Streptococcus* spp. (particularly *S viridans*) and *Enterococcus* spp, which together cause more than 80% of IE. Although several authors consider *S viridans* to be the most frequent microorganism in the first year of life, in Argentina *S aureus* predominates in both children and adults. In contrast, *Enterococcus* spp is less common in children than in adults<sup>1</sup>.

Pneumococcal endocarditis is a rare condition. An incidence of 1-7% is described in the literature<sup>3,4,5</sup>. In a study conducted at J. P. Garrahan Hospital, it was found that 8% of IE diagnosed between 1988 and 2006 had pneumococcal identification<sup>7</sup>.

The clinical picture of IE from *S pneumoniae* is usually acute and severe, as in the case presented. In a review of 11 pediatric cases by Givner et al. all patients had fever, 73% gastrointestinal symptoms, 64% chills and asthenia or weakness, and 45% of children had heart murmur or modification of a pre-existing one.<sup>3</sup> Another study published by Choi et al. describes the appearance of a new heart murmur as the most frequent sign of presentation<sup>8</sup>.

In our patient, the presence of fever and previously undocumented heart murmur associated with heart failure were very suggestive signs of IE.

Large vegetations in pneumococcal IE are also described, and hemodynamic instability and systemic embolisms are common. Skin lesions characteristic of IE, such as Janeway disease or Osler's nodes, are uncommon in pneumococcal endocarditis<sup>8</sup>.

The Osler's triad or Austrian syndrome, typical of pneumococcal IE, consists on the association of pneumonia, meningitis, and endocarditis due to *S pneumoniae*. This triad occurs in about half of the cases and it is associated with extensive valve damage and high mortality (about 50% in some series of cases)<sup>4,9</sup>.

Pneumococcal IE occurs in 87-92% in native valves<sup>10</sup>. The involvement of the mitral valve in IE by this agent is described in the literature. It can also affect the aortic and tricuspid valve<sup>8</sup>.

The diagnosis of IE in children is based on clinical suspicion, microbiological findings, and echocardiogram. Unlike IE in adults, TTE in pediatrics has a 97% sensitivity<sup>11</sup>, but TEE (transesophageal echocardiography) may be required, especially in cases of leaks or perivalvular dehiscences, complications in the outflow tract of the left ventricle, compromise of the sinuses of Valsalva, endocarditis on prosthetic valves, and in children with transthoracic window limitations (congenital or acquired rib cage abnormalities, intracardiac prosthetic material, chest wall disruption due to trauma or previous surgeries)<sup>12</sup>. In those patients with high suspicion of IE in which no vegetations are documented in TTE, it may be neces-

sary to repeat it within 5 to 7 days after the initial diagnosis and eventually complete the evaluation with a TEE<sup>13</sup>. In the patient presented, the endocardial compromise was evidenced in the TTE performed at admission.

The child presented in this report had received one single dose of 10-valent pneumococcal conjugate vaccine. The serotypes contained in this vaccine are 1, 5, 4, 6B, 7F, 9V, 14, 18C, 19F and 23F14. In this case the identified *S pneumoniae* serotype 6A was not included in such vaccine.

The antibiotic treatment should be adjusted to the identified microorganism and antibiotic sensitivity. The recommended treatment for IE for penicillin-sensitive streptococcus, including pneumococcus, is the combination of penicillin G or third-generation cephalosporins with gentamicin, with a total duration of treatment of 4 weeks<sup>12</sup>. Argentina participates in a system that documents the antibiotic sensitivity of pneumococcus. Such system is called System of Networks for Surveillance of the Bacterial Agents Responsible for Pneumonia and Meningitis (SIREVA) and its aim is the regional surveillance of antibiotic sensitivity and predominant serotypes. The 2012 report highlights the decrease in penicillin resistance to 0.7% and 1.5% to third-generation cephalosporins in strains of *S pneumoniae* invasive infections<sup>15</sup>.

In a study that included 171 pneumococcal bacteremias in children between 2008 and 2013, all isolates were sensitive to penicillin, cefotaxime, and ceftriaxone<sup>16</sup>.

Exclusive antibiotic treatment in IE may be insufficient. Surgery should be considered in the event of cardiac failure or persistent bacteremia refractory to treatment, severe valve failure (aortic or mitral) with associated ventricular failure, in large vegetations or in the event of major embolic phenomena. Surgery is not recommended to prevent an embolic event because it is not proven to be beneficial and because of the long-term risks of childhood valve replacement<sup>12</sup>.

An early surgical intervention in patients with pneumococcal IE and hemodynamic instability was associated with a significant reduction in mortality<sup>2,8</sup>.

## Conclusion

Although IE is a rare childhood disease, its high morbidity and mortality compel us to have a high index of suspicion in order to make an early diagnosis and start appropriate treatment.

Despite the decrease in the incidence of invasive pneumococcal infections since the introduction of the conjugate vaccine, these infections should be suspected for non-vaccinal serotypes in febrile patients with severe community-acquired infections.

Diagnosis of IE should be considered among the differential diagnoses of all febrile children with the appearance of a new heart murmur.

## Ethical Responsibilities

**Human Beings and animals protection:** Disclosure the authors state that the procedures were followed according to the Declaration of Helsinki and the World Medical Association regarding human experimentation developed for the medical community.

**Data confidentiality:** The authors state that they have followed the protocols of their Center and Local regulations on the publication of patient data.

**Rights to privacy and informed consent:** The authors have obtained the informed consent of the patients and/or subjects referred to in the article. This document is in the possession of the correspondence author.

## Financial Disclosure

Authors state that no economic support has been associated with the present study.

## Conflicts of Interest

Authors declare no conflict of interest regarding the present study.

## References

- 1 Nacinovich F, Stamboulia D. Capítulo 72: Endocarditis. Paganini H. Infectología Pediátrica. 1ra edición. Buenos Aires: Editorial Científica Interamericana;2007, p481-96.
- 2 Aronin S L, Mukherjee S K, West J C, Cooney E L. Review of pneumococcal endocarditis in adults in the penicillin era. Clin Infect Dis 1998; 26: 165-71.
- 3 Givner LB, Mason EO Jr, Tan TQ, Barson WJ, Schutze GE, Wald ER et al. Pneumococcal endocarditis in children. Clin Infect Dis 2004; 38:1273-8.
- 4 Kan B, Ries J, Normark BH, Chang FY, Feldman C, Ko WC et al. Endocarditis and pericarditis complicating pneumococcal bacteraemia, with special reference to the adhesive abilities of pneumococci: results from a prospective study. Clin Microbiol Infect 2006;12:338-44.
- 5 Ishiwada N, Niwa K, Tateno S, Yoshinaga M, Terai M, Nakazawa M. Pneumococcal endocarditis in children: a nationwide survey in Japan. Int J Cardiol 2008; 123:298-301.
- 6 Clinical and Laboratory Standards Institute. 2014. Performance standards for antimicrobial susceptibility testing. 24th informational supplement (January 2015), document M100-S25
- 7 Villa A, Sarkis C, Paganini H, Casimir L. Streptococcus pneumoniae Infectious Endocarditis in Children: 17 years Experience in Argentina. IDSA 2007. Presentación poster.
- 8 Choi M, Lloid Mailman T. Pneumococcal endocarditis in infants and children. Pediatr Infect Dis J 2004; 23: 166-71.
- 9 Austrian R. Pneumococcal endocarditis, meningitis, and rupture of the aortic valve. AMA Arch Intern Med. 1957; 99:539-44.
- 10 Martínez E, Miró JM, Almirante B, Aguado JM, Fernández-Viladrich P, Fernández-Guerrero ML, et al. Effect of penicillin resistance of Streptococcus pneumoniae on the presentation, prognosis, and treatment of pneumococcal endocarditis in adults. Clin Infect Dis. 2002;35: 130-9.
- 11 Penk JS, Webb CL, Shulman ST, Anderson EJ. Echocardiography in pediatric infective endocarditis. Pediatr Infect Dis J. 2011;30:1109-11
- 12 Baltimore RS, Gewitz M, Baddour LM, Beerman LB, Jackson MA, Lockhart PB et al. Circulation. 2015;132:1487-1515
- 13 Habib G, Lancellotti P, Antunes MJ, Bongiorni MG, Casalta JP, Del Zotti F et al. 2015 ESC Guidelines for the management of infective endocarditis. Eur Heart J. 2015; 36: 3075-128
- 14 World Health Organization. Pneumococcal vaccines WHO position paper—2012—recommendations. Vaccine. 2012;30:4717-8
- 15 Informe Regional SIREVA II 2012: Datos por país y por grupos de edad sobre las características de los aislamientos de Streptococcus pneumoniae, Haemophilus influenzae y Neisseria meningitidis, en procesos invasores. Washington, D.C.: OPS, 2013. Disponible en: [http://new.paho.org/hq/index.php?option=com\\_content&view=category&layout=blog&id=3609&Itemid=3953](http://new.paho.org/hq/index.php?option=com_content&view=category&layout=blog&id=3609&Itemid=3953). Último acceso Octubre 2016
- 16 G. Pérez, A. Mastroianni, A. Parra, L. Casimir, V. Reijtman, H. Lopardo, R. Bologna. Infecciones invasivas con bacteriemia por Streptococcus pneumoniae en niños: ¿qué pasó en los últimos 5 años? Revista Medicina Infantil XXI (4):318-324.