

## Minimally invasive therapy for the resolution of a subcapsular hepatic hematoma in a newborn

### Terapia mínimamente invasiva para el manejo de un hematoma subcapsular hepático en un recién nacido

María Santos C.<sup>a,b</sup>, Gian Paolo Zamboni T.<sup>c</sup>, Daniel Hasson<sup>b,d</sup>, Marina Poblete S.<sup>c</sup>, Patricio Vargas H.<sup>c</sup>

<sup>a</sup>Becado de Cirugía Pediátrica. Hospital Padre Hurtado, Clínica Alemana de Santiago. Santiago, Chile

<sup>b</sup>Facultad de Medicina Clínica Alemana-Universidad del Desarrollo. Santiago, Chile

<sup>c</sup>Clínica Alemana Santiago. Santiago, Chile

<sup>d</sup>Becado de Radiología, Hospital Padre Hurtado, Clínica Alemana de Santiago. Santiago, Chile

Received: April 30, 2020; Approved: August 18, 2020

#### What do we know about the subject matter of this study?

Liver hematomas are one of the complications of umbilical vein catheterization in newborns. In the case of surgery, laparotomy is currently the treatment of choice.

#### What does this study contribute to what is already known?

Hepatic artery embolization by angiography is an innovative alternative for the management of a newborn with a subcapsular liver hematoma. It is a procedure with fewer comorbidities and complications than exploratory laparotomy.

#### Abstract

**Objective:** To describe an innovative alternative to exploratory laparotomy in a newborn with a subcapsular hepatic hematoma secondary to umbilical vein catheterization. **Clinical Case:** A preterm baby with a history of hyaline membrane disease, pulmonary hypertension, and large patent ductus arteriosus, requiring mechanical ventilation and the use of vasoactive drugs. Umbilical catheters were inserted and through an abdomen X-ray, we observed their proper position. The patient evolved with greater requirements of vasoactive drugs, abdominal wall pallor, and abdominal distention. Abdominal ultrasound showed a subcapsular hepatic hematoma, with no signs of active bleeding, so expectant management was decided. The patient required increased vasoactive drugs and presented a decrease in hematocrit. New ultrasound showed a larger subcapsular hematoma, abundant perihepatic fluid, and the intraparenchymal position of the umbilical catheter was confirmed. Endovascular embolization was performed through the umbilical catheter with Gelita®, achieving occlusion of the capsular path. Posterior ultrasound showed a reduction of the hematoma. **Conclusions:** The use of embolization through angiography is not commonly used in pediatric emergencies. It is a procedure

#### Keywords:

Hematoma; Liver; Angiography; Catheterization; Umbilical Veins; Newborn

Correspondence:  
María Santos C.  
mariasantosc@gmail.com

re with fewer comorbidities and complications than exploratory laparotomy, therefore it should be considered as first-line therapy in patients like the one presented above. The limitation for its routine performance is the lack of available angiography operating room and trained interventional radiology team.

## Introduction

The use of umbilical catheters in newborns is a commonly used technique, with different complications. It is estimated that only 73% of the catheters are placed at an adequate level<sup>1</sup>. Among the complications described are malpositioning, infection, thrombosis, perforation, and liver complications which may include perforation, laceration, sterile abscess, hematoma, or ascites<sup>2</sup>. Currently, severe hepatic complications require surgical management.

We present a clinical case of a newborn who presented a subcapsular hematoma secondary to an umbilical venous catheterization, which had minimally invasive management with angiography and absorbable hemostatic material (Gelita®), with a successful outcome and a favorable evolution.

The objective of this clinical case is to show a less invasive therapeutic alternative for the management of these lesions.

## Clinical Case

A 32-week preterm twin I newborn, appropriate for gestational age, born by cesarean section due to preterm labor. He presented hyaline membrane disease, anemia, pulmonary hypertension, and large patent ductus arteriosus. He was treated with high-frequency oscillatory ventilation, pulmonary surfactant, indomethacin, fentanyl, hydrocortisone, and dopamine due to unstable arterial pressure.

At one day of life, an umbilical arterial catheter (UAC) and an umbilical venous catheter (UVC) were placed for the administration of parenteral nutrition and medication. After placing the catheters, anteroposterior control X-ray image was taken (Figure 1), showing the arterial catheter at the D8 level and the venous one visualized in the inferior vena cava, both in apparently the right place.

On the fifth day of life, the patient remained in severe condition, presenting with abdominal distension associated with abdominal wall pallor and signs of hypoperfusion in the lower abdomen, hematocrit level of 41%. The UAC was removed, indicating not to use the venous catheter, and an abdominal X-ray was performed, which showed no pathological findings. The

abdominal ultrasound showed a significant amount of free intraperitoneal fluid with echogenic particles (consistent with hemoperitoneum), abundant hepatic subcapsular fluid, and gas within a cystic focal hepatic lesion, in close contact with the UVC, suggestive of intraparenchymal and subcapsular hepatic hematoma (Figures 2 and 3). These findings were interpreted as a complication of UVC malposition, and it was decided expectant management, delaying the UVC removal (which remained unused), and ultrasound control in 48hrs or earlier, in case of deterioration.

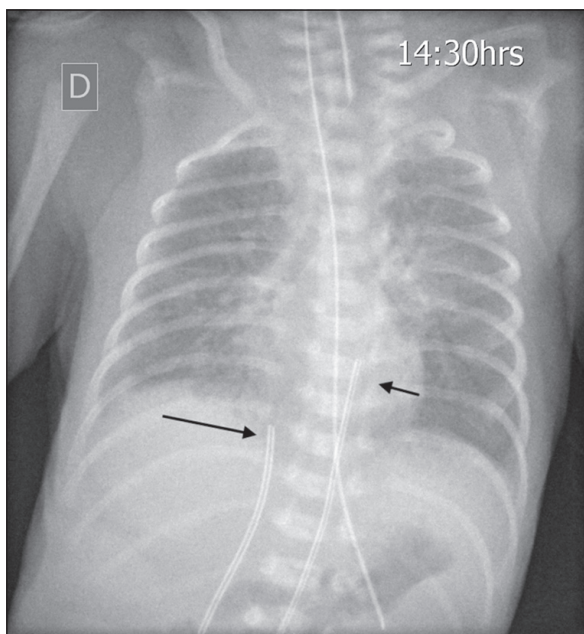
The following day, he showed improvement of the abdominal wall color, soft abdomen but hemodynamic lability, hematocrit drop to 29%, and increased requirements of vasoactive drugs. A new ultrasound showed an enlarged subcapsular hematoma, the distal end of the UVC inside it, and perihepatic free fluid with similar characteristics to the previous study (Figure 4).

Due to the poor clinical progress and imaging findings, it was decided to perform angiography. We accessed through the umbilical catheter, observing subcapsular contrast extravasation, as well as into the intrahepatic hematoma. Selective angiographic embolization of the hematoma and the intraparenchymal segment was performed through the same catheter with absorbable hemostatic material (Gelita®), until achieving the capsular segment occlusion (Figure 5). The procedure was performed without incidents, and the UVC was subsequently removed. The patient progressed favorably, presenting a progressive increase of hematocrit to 42% and progressive decrease of vasoactive drug requirements. 2 months after surgery, a control ultrasound showed no complications and the intraparenchymal hematoma was smaller, with no evidence of signs of recent bleeding.

## Discussion

Hepatic hematomas are rare in newborns, however, they are underdiagnosed since they are generally asymptomatic and sometimes they are a finding in autopsies<sup>3</sup>. Generally, these hematomas are subcapsular in location.

It has been postulated that premature newborns present a hepatic capsule of greater fragility in the col-



**Figure 1.** Abdominal radiography post-installation of umbilical catheters. An arterial catheter is observed at the level of D8 (short arrow) and a venous catheter projected at the confluence of the venous duct with the inferior vena cava (long arrow).

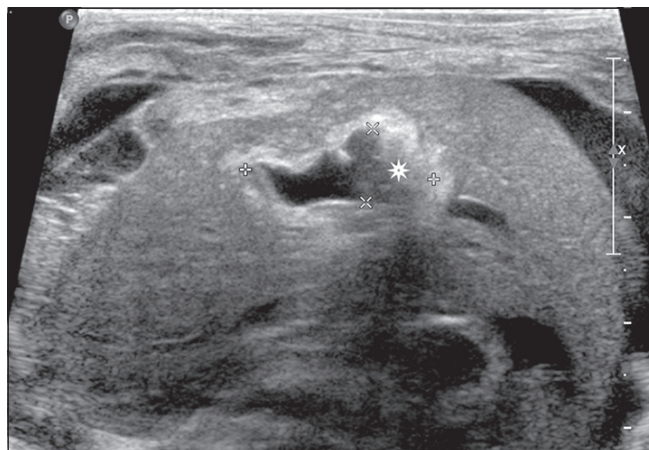
lagen fibers that connect it to the parenchyma, which would be part of the pathogenesis of these hematomas<sup>4</sup>.

When the hematoma is larger than 3-4 cm or the capsule can no longer contain it, it becomes symptomatic. This increases the risk of generating hemoperitoneum, which can lead to hypovolemic shock with high mortality.

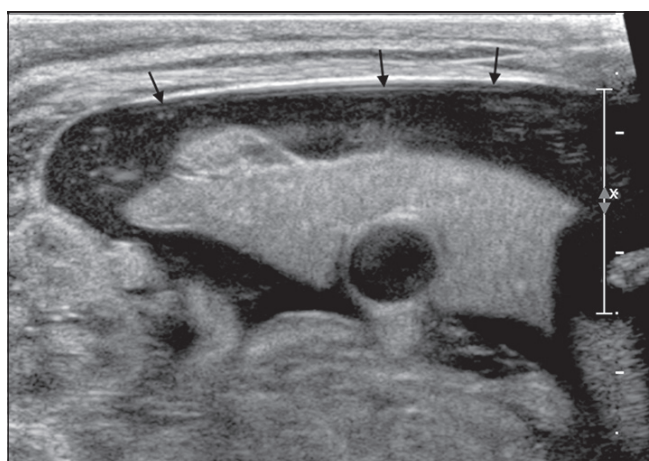
There is a variety of etiologies of subcapsular hematomas which are mostly traumatic, as well as secondary to coagulopathies, hypoxia, sepsis, tumors, or congenital vascular malformations<sup>3</sup>. Compression of thoracic and abdominal structures can stretch the coronary ligament inserted in the diaphragm causing a laceration and subcapsular hematoma. This could explain that vaginal delivery is a possible cause of hepatic hematomas.

The clinical suspicion of hepatic complications is based on the presence of sudden abdominal distension, associated with hypotension and anemia, and may also present with anuria or acute portal hypertension<sup>2</sup>. The diagnosis is confirmed by imaging studies, where ultrasound and MRI are the diagnostic modalities of choice, depending on the patient's symptoms and history. CT scan is also considered a good alternative in case the previous ones are not available<sup>5</sup>.

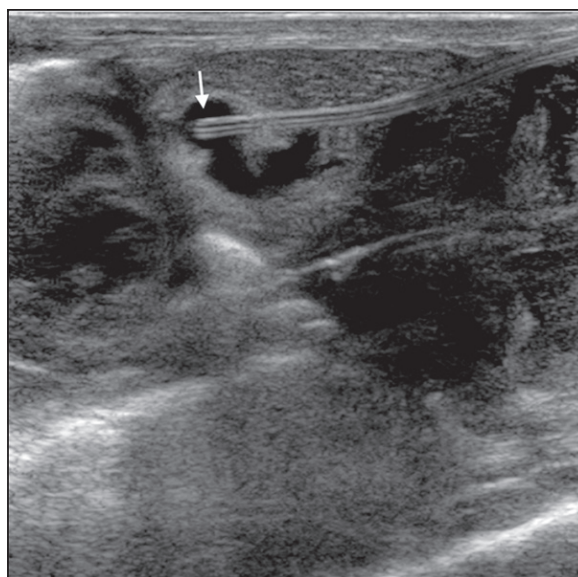
The management of patients with subcapsular hematomas without hemodynamic alteration or signs of active bleeding is conservative, with serial ultrasound



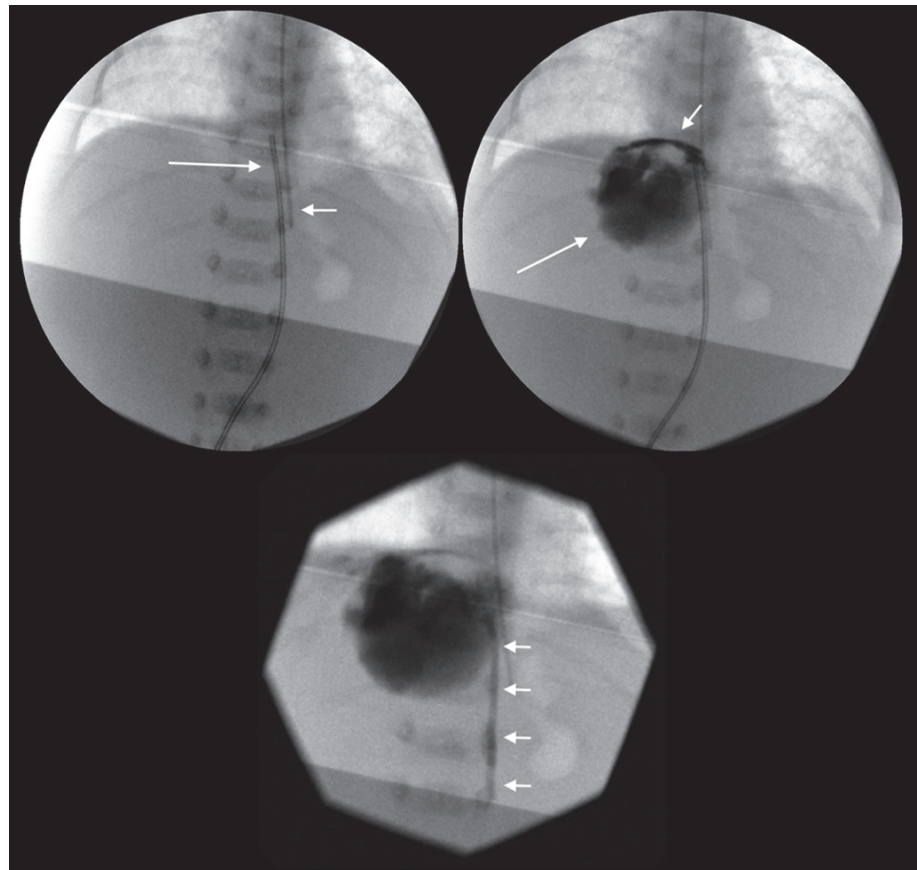
**Figure 2.** Abdominal ultrasound. Cystic image with anfractuous edges and a "dirty shadow" inside, corresponding to an intrahepatic hematoma with air.



**Figure 3.** Abdominal ultrasound. Extensive subcapsular hepatic hematoma (arrows).



**Figure 4.** Abdominal ultrasound. Tip of the catheter inside the intrahepatic hematoma.



**Figure 5.** Fluoroscopic images during the procedure. Venous catheter (long arrow) and feeding tube (short arrow) are observed **(a)**. After administration of contrast through the catheter, the intrahepatic hematoma becomes evident (long arrow) and signs of subcapsular bleeding are also identified (short arrow) **(b)**. Post-embolization image, the umbilical catheter has been removed and radiopaque embolization material is observed in the path of the catheter (short arrows) **(c)**.

monitoring due to the risk of rupture, bleeding, or infection. In most cases, there is a spontaneous resolution after 6-8 weeks. In patients with hemodynamic instability or symptoms of active bleeding, vascular control is necessary. Exploratory laparotomy with packing of the bleeding area is the most commonly adopted measure, however, this technique presents high risk, associated with comorbidities and complications of the surgical procedure. An option to this technique is interventional radiology which allows embolization of the bleeding vessel.

Considering the risks of laparotomy in labile patients, the spectrum of minimally invasive techniques appears as an attractive alternative. Vascular access is a particularly challenging aspect of pediatric vascular interventional procedures. The umbilical vein is a valuable option for newborns which is used relatively frequently in neonatal units and remains permeable around 7 days after birth<sup>6,7</sup>.

In the case of a similar procedure, Luetic et al. describe the embolization of a rapidly involuting congenital hemangioma (RICH) through umbilical veins, however, in that case, it was used to access the arterial area through a patent foramen ovale<sup>8</sup>. It is necessary to weigh the risks inherent to these procedures in pediat-

ric patients, trying to minimize the radiation dose and to monitor the appearance of complications, which are mainly vascular (hematomas, dissection, thrombosis, and pseudoaneurysms)<sup>6</sup>.

The images used to check for proper catheter placement are ultrasound or anteroposterior and lateral radiography. Abdominal X-ray is currently the most widely used method for imaging control after catheter insertion, however, according to Michel et al. ultrasound is superior to radiography for locating the catheter tip, as it also offers better visualization of vascular structures<sup>9</sup>. Derinkuyu et al. also recommend strict monitoring of catheter insertion with ultrasound<sup>5</sup>. This case shows its usefulness for post catheter insertion monitoring, as well as for signs of complications.

In this case, we describe an alternative technique for the management of these patients, by minimally invasive intervention, performing umbilical vein angiography until the bleeding site is found, and then introducing absorbable hemostatic material through the catheter, achieving adequate hemostasis. After the procedure, the patient should be followed up with ultrasound monitoring to ensure the absence of bleeding and resolution of the hematoma.

## Conclusion

In recent years, the use of image-guided minimally invasive techniques has been widely used in adults and has been progressively introduced in pediatrics. Endovascular embolization of the bleeding point causing subcapsular hematoma becomes a feasible and less invasive alternative to the usual surgical techniques in this serious complication. It is important to highlight, especially for the Chilean reality, that the lower availability of angiography units and trained interventional radiology teams limits the common use of this procedure. It is an alternative therapy but should not delay surgical indication if the equipment is not available.

## Ethical Responsibilities

**Human Beings and animals protection:** Disclosure the authors state that the procedures were followed according to the Declaration of Helsinki and the World

Medical Association regarding human experimentation developed for the medical community.

**Data confidentiality:** The authors state that they have followed the protocols of their Center and Local regulations on the publication of patient data.

**Rights to privacy and informed consent:** The authors have obtained the informed consent of the patients and/or subjects referred to in the article. This document is in the possession of the correspondence author.

## Conflicts of Interest

Authors declare no conflict of interest regarding the present study.

## Financial Disclosure

Authors state that no economic support has been associated with the present study.

## References

1. Haase R, Hein M, Thäle V, Vilser C, Merkel N. Umbilical venous catheters-analysis of malpositioning over a 10-year period [en alemán]. *Z Geburtshilfe Neonatol* 2011;215:18-22.
2. Grizelj R, Vukovic J, Bojanic K, et al. Severe Liver injury while Using Umbilical Venous Catheter: Case Series and Literature Review *Am J Perinatol*. 2014;31:965-74.
3. Costa S, De Carolis M, Savarese I, Lacerenza S, Romagnoli C. Hepatic Hematoma in a Neonate With a High Level of Alpha-Fetoprotein. *Eur J Pediatr*. 2008;167:591-3.
4. Singer DB, Neave C, Oyer CE, Pinar H. Hepatic subcapsular hematomas in fetuses and neonatal infants. *Pediatr Dev Pathol*. 1999;2:215-20.
5. Derinkuyu BE, Boyunaga OL, Damar C, et al. Hepatic complications of umbilical venous catheters in the neonatal period. *J Ultrasound Med*. 2018;37:1335-44.
6. Heran MK, Marshalleck F, Temple M, et al. Joint quality improvement guidelines for pediatric arterial access and arteriography: from the Societies of Interventional Radiology and Pediatric Radiology. *Pediatr Radiol*. 2010;40:237-50.
7. Álvaro RE, Rigatto H. Cardiorespiratory adjustments at birth. En: *Avery's Neonatology Pathophysiology & Management of the Newborn*. 6ta ed. Philadelphia: Lippincott Williams & Wilkins, 2005:285-303.
8. Luetić T, Radoš M, Vuković J, et al. Embolization of a Rapidly Involuting Congenital Hepatic Hemangioma via the Umbilical Vein in a Neonate. *J Vasc Interv Radiol*. 2019;30:1625-8.
9. Michel F, Brevaut-Malaty V, Pasquali R, et al. Comparison of ultrasound and X-ray in determining the position of umbilical venous catheters. *Resuscitation* 2012;83:705-9.