



## Fat necrosis of the newborn

### Necrosis grasa del recién nacido

Daniel López Hurtado<sup>a</sup>, Mario Elías Delgado<sup>b</sup>, Javier Ortega Díaz<sup>b</sup>, Marco Solís Avaca<sup>b</sup>,  
Heyssel Carmona Alvarado<sup>b</sup>, Cecilia Cabello Durán<sup>c</sup>

<sup>a</sup>Unidad de Neonatología, Servicio de Pediatría, Hospital San Juan de Dios de Curicó, Chile

<sup>b</sup>Hospital San Juan de Dios de Curicó, Chile

<sup>c</sup>Estudiante de Medicina, Facultad de Ciencias Médicas, Universidad de Talca, Chile

Received: 29-3-2019; Approved: 3-8-2019

#### What do we know about the subject matter of this study?

Subcutaneous fat necrosis (SCFN) of the newborn (NB) is a rare disorder characterized by nodules and erythematous plaques, usually in full-term NBs. It often follows a self-limiting course but can be complicated by hypercalcemia, among others.

#### What does this study contribute to what is already known?

An original contribution where we present a patient with Ebstein anomaly which could represent a risk factor for the development of SCFN since there are other congenital heart diseases described in the literature associated with SCFN.

#### Abstract

**Introduction:** Panniculitis is a group of diseases that affect subcutaneous fat tissue and clinically manifest as nodules. Its pathogenesis is not entirely clear, and it is usually asymptomatic. The confirmatory diagnosis is histological. **Objective:** To describe the clinical and histopathological characteristics of a case of fat necrosis, a specific form of panniculitis in the newborn (NB). **Clinical Case:** 40-week female NB, born by emergency cesarean section due to fetal tachycardia with meconium, Apgar score 7-8-9. She required oxygen and positive pressure for five minutes. On the fifth day of life, she presented an increased volume in the posterior trunk region, with an erythematous - purplish discoloration, which is soft and non-tender to palpation. Skin and soft tissues ultrasound showed increased echogenicity of the subcutaneous cellular tissue and loss of definition of the adipocytes of 42.3 x 9.7 x 20.1 mm approximately, without vascularization. Skin biopsy showed epidermis with irregular acanthosis and basket-weave orthokeratosis; papillary dermis with inflammatory infiltrate, and reticular dermis and adipose tissue with presence of lymphohistiocytic infiltrate with a tendency to form nodules, without vascular involvement, and small cholesterol deposits, compatible with subcutaneous fat necrosis (SBFN) of the newborn. The patient at three months of age had complete regression of the lesion. **Conclusions:** a clinically and histologically compatible case with SBFN is described, that did not present complications during observation. In general, this pathology has a good prognosis, with spontaneous resolution as in our case.

**Keywords:**  
panniculitis;  
fat necrosis;  
newborn;  
neonatology

Correspondence:  
Daniel López Hurtado  
danlophurtado@gmail.com

## Introduction

Panniculitis is a group of diseases of widely varying etiology that affect subcutaneous fat tissue. They may be idiopathic or associated with different metabolic or autoimmune diseases, neoplasms, drugs, and physical or infectious agents<sup>1</sup>.

Clinically, they appear as nodules in the subcutaneous tissue. The age of the patient and the location of the lesions may help in the clinical diagnosis, however, histopathology is important for confirming the diagnosis. Panniculitis can be classified as septal or lobular depending on the involvement of the hypodermis (table 1). There are specific panniculitis in childhood such as SCFN of the NB, sclerema neonatorum, post-steroid panniculitis, and due to cold exposure, all of them histologically within the lobar pattern<sup>2</sup>.

The objective of this paper is to describe the clinical and histopathological characteristics of a case of SCFN, a specific form of panniculitis in the NB, which is rare in clinical practice.

## Clinical Case

Full-term female NB, with features according to gestational age, newborn of monitored pregnancy, birth weight 3,655 g and length 50 cm. Non-sensitized negative Rh child. Emergency C-section was performed due to fetal tachycardia plus meconium, APGAR score 7-8-9. She required oxygen and positive pressure ventilation for five minutes. Meconium fluid secretions were aspirated. No physical findings of dysmorphism. Negative direct Coombs test and venous cord blood gas were normal.

The patient was admitted to the intermediate care unit of neonatology due to history of neonatal depression and respiratory distress (only tachypnea and bilateral rales on lung auscultation). She required room air for 12 hours and then through nasal cannula until 21 hours of age, with normal chest X-ray. After 24 hours of age, the patient showed no signs of respiratory distress. The blood count before 24 hours of life showed leukopenia, C-reactive protein (CRP) and procalcitonin (PCT) tests were altered, therefore, and after taking samples for blood cultures that were negative, empirical antibiotic therapy was started with Ampicillin and Amikacin for seven days. (You may want to include antibiotic doses here)

On the second day of life, a systolic murmur grade III/VI was found thus she was evaluated by pediatric cardiology. Echocardiogram was performed concluding Ebstein anomaly type B (Carpentier et al), medium ventricular septal defect, mild tricuspid valve regurgitation, and patent foramen ovale, without signs of pul-

monary hypertension.

On the fifth day of life, the patient presented volume increase in the posterior median line, multiple erythematous and indurated nodules, fixed in the underlying tissue, 5 cm in their greater diameter when occurring vascular convergence, and apparently non-tender (Figure 1). CBC, PCR, PCT, coagulation time, glycemia and calcium were measured, all within normal ranges. Skin and soft tissue ultrasound showed an increase in the echogenicity of subcutaneous cellular tissue with definition loss around 42.3 x 9.7 x 20.1 mm of fat cells which, in the color Doppler ultrasound, showed no evident vascular alterations.

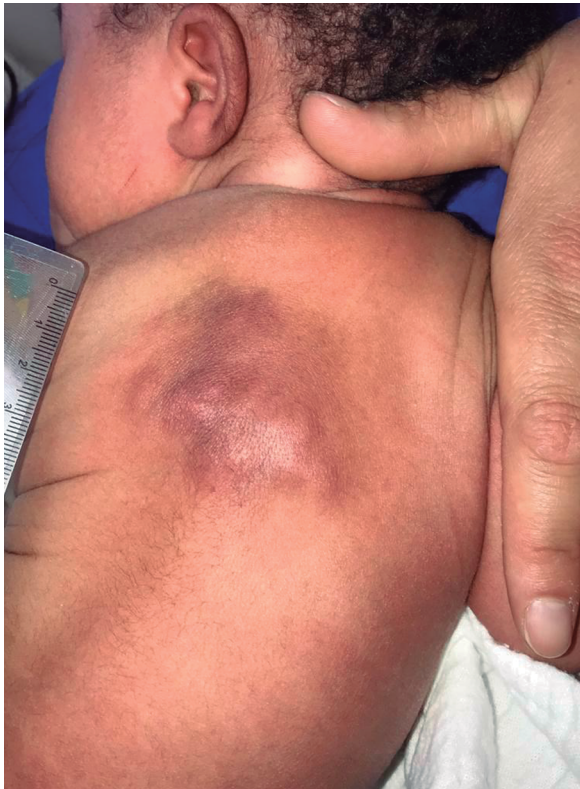Biopsy of the lesion showed epidermis with irregular acanthosis and basket-weave orthokeratosis; papillary dermis with inflammatory infiltrate, and reticular dermis and adipose tissue with lymphohistiocytic infiltrate with tendency to nodule formation, without vascular involvement, and small cholesterol deposits. These morphological findings were compatible with SCFN of the NB (Figure 2). In addition, samples of the skin lesion were taken for aerobic culture, gram stain, and culture of Koch's bacillus which were all negative. Altogether, it was concluded that SCFN of the NB was diagnosis.

The patient was seen for follow ups as outpatient with pediatrics, cardiology, and dermatology. At one month of age, the regression of the lesion started until it disappeared at three months of age. Blood calcium was monitored until the fourth month of life which was normal for age.

## Discussion

SCFN is a benign form of panniculitis whose onset may vary throughout the neonatal period<sup>3</sup>. It is a rare condition and its specific incidence is unknown. Del Pozzo-Magaña and Nhung Ho<sup>4</sup> in a 20-year retrospective study of SCFN report almost equal proportions of male to female (1.14: 1)<sup>4</sup>. It most often develops in full-term NBs (more than 37 weeks of gestational age) who have suffered hypoxia or other perinatal stress. Other risk factors include a) Neonatal: therapeutic hypothermia as treatment for asphyxia<sup>5</sup>, meconium aspiration syndrome, umbilical cord prolapse, sepsis, intestinal perforation, and congenital heart disease<sup>6</sup>; and b) Maternal: pre-eclampsia, gestational diabetes, substance use (calcium channel blockers, cocaine), tobacco use and/or passive exposure, and Rh incompatibility<sup>6,7</sup>. In our case, the patient presented Ebstein anomaly-type congenital heart disease, and to the best of our knowledge, it is the first time this association has been seen.

The pathogenesis of SCFN is still unclear. One hypothesis proposes that it could be the result of the

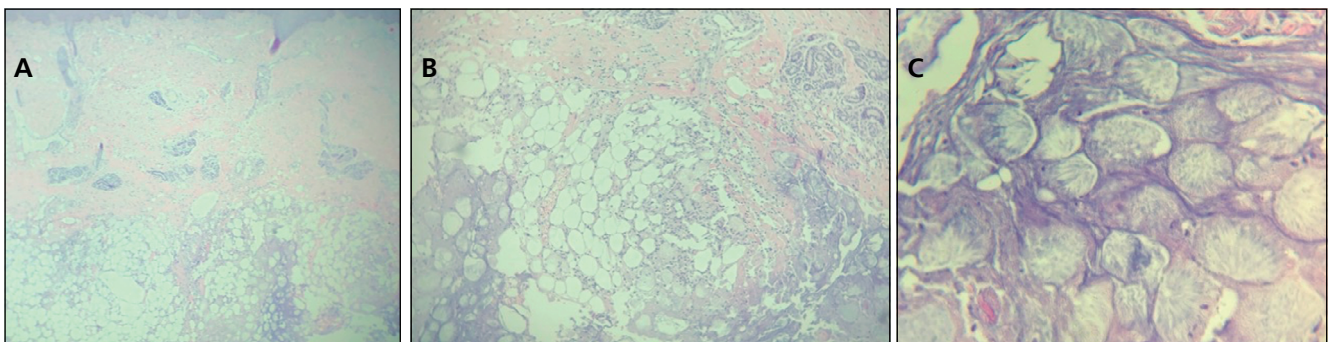


**Figure 1.** New born with confluent nodular lesions, erythematous in posterior trunk.

**Table 1. Pediatric panniculitis: lobular and septal inflammatory patterns**

Predominantly lobar panniculitis	Predominantly septal panniculitis
Subcutaneous fat necrosis of the new born <sup>a</sup>	Erythema nodosum
Esclerema neonatarum <sup>a</sup>	Granulomatous panniculitis
Post-steroids Paniculitis <sup>a</sup>	Granuloma annulare subcutaneous
Physical	Cutaneous polyarteritis nodosa
Cold panniculitis <sup>a</sup>	
Injections	
Trauma	
Infectious panniculitis	
Fungal	
Bacterial	
Erythema induratum of De Bazin	
Enzymatic panniculitis	
Alfa-1 anti-trypsin deficiency	
Pancreatic panniculitis	
Granulomatous paniculitis	
Sub-cutaneous sarcoidosis	
Connective tissue diseases	
Lupus panniculitis	
Panniculitis in dermatomyositis	
Histiocytic cytophagic panniculitis	
T-cell lymphoma subcutaneous panniculitis <sup>b</sup>	

<sup>a</sup>Specific panniculitis in pediatrics; <sup>b</sup>Not truly panniculitis.



**Figure 2.** Histopathology. Hematoxylin and Eosin. (A) Deep dermis with lobular panniculitis without vasculitis (40X). (B) Abundant lymphohistiocytic inflammatory infiltrate, nodular pattern in adipose tissue with multinucleated giant cells (100X). (C) Intra-cytoplasmic lipidic crystals, radial distribution, suggestive of fat necrosis (400X).

combination of local tissue hypoxia and mechanical pressure, and another one suggests that enrichment of saturated stearic and palmitic acids in neonatal fat predisposes the tissue to crystallization at low temperatures<sup>4</sup>.

Clinically, it is characterized by multiple indurated plaques or nodules, with or without erythema on the cheeks, posterior trunk, buttocks, and limbs, while the anterior trunk and abdomen are usually not affected<sup>3</sup>. Our patient developed subcutaneous nodules and erythema on the posterior trunk within the first days

of life. Del Pozzo-Magaña and Nhung Ho report that nodules and erythema appear in 100% and 73% respectively of SCFN cases, and 50% of the time, lesions appear on the back of the affected NB<sup>4</sup>.

The SCNF diagnosis can be made clinically, however, the confirmation of it is through histopathological studies. The findings include: lobular panniculitis with dense infiltrate of histiocytes, eosinophils, and multinucleated giant cells, radial crystal-like cleft spaces in matrices within adipocytes, and focal calcification within lesions without vasculitis<sup>8</sup>. All these findings

were compatible with the skin biopsy of our NB. If in doubt, MRI and ultrasound may also be useful in the evaluation of lesions<sup>8,9</sup>.

The resolution of most lesions occurs spontaneously in weeks to months leaving no sequelae on the skin<sup>9</sup>, and in some cases, the affected fat liquefies in the fluctuating blisters or cutaneous atrophy may also develop<sup>10</sup>. The injury regression of our patient started from one month of life until it completely disappeared at three months of age. Same time of regression from onset of the injury as described by Avayú E<sup>11</sup>.

Approximately 25% of patients are in pain and require appropriate analgesic treatment<sup>3</sup>. SCFN is usually a transitory and self-limiting condition, however, complications such as hypercalcemia, thrombocytopenia, hypoglycemia, and hypertriglyceridemia may occur<sup>4</sup>. Hypercalcemia occurs in 36-56% of affected neonates<sup>12</sup> and it may be severe and/or lethal. The specific etiology is unknown, however, it is likely that cells from granulomatous inflammation express high levels of 1-alpha-hydroxylase, the enzyme that catalyzes 25-hydroxyvitamin D3 into its active form of 1,25-dihydroxyvitamin D3 that may promote calcium mobilization of bones and increase its intestinal absorption<sup>13</sup>. Also, it can be asymptomatic or present as irritability, hypotonia, anorexia, or vomiting.

Nephrocalcinosis and metastatic calcification in other tissues (pericardium and brain) have been associated with SCFN of the NB<sup>14,15</sup>. Therefore, serum calcium levels should be monitored for up to six months after the onset of skin lesions. It is treated through the restriction of calcium and vitamin D supplements, hyperhydration with intravenous fluids, and loop diuretics, and in more severe cases, systemic corticosteroids and biphosphonates have been used<sup>3,16</sup>. In our case, none of the complications described were observed, and in the monthly outpatient follow-up, the serum calcium levels were normal in the first 4 months of life.

The differential diagnoses of SCFN in addition to another panniculitis of the NB (sclerema neonatorum (SN), post-steroid panniculitis, and due to cold exposure) are hemangioma, cellulitis, histiocytosis, Farber disease, fibromatosis, and rhabdomyosarcomas, which are histologically different<sup>17</sup>.

Regarding SN, the risk factors described include acutely ill NB, low-birth-weight preterm NB, sepsis, congenital heart disease, among others<sup>18</sup>, and it is associated with a high mortality rate, about 75%<sup>19</sup>. The lesions appear in the first days of life, initially on the buttocks and thighs and then they spread rapidly to cover large areas of the body<sup>18</sup>, without involving genitals, palms, and soles, which lack subcutaneous fat tissue. The thickened skin may appear waxy, purple or mottled. There may be functional limitations of the joints, altered chest wall movement, and difficulty

feeding. Histopathology shows adipocytes containing needle-shaped clefts, but the lack of inflammatory cells differentiates it from SCFN<sup>18</sup>. The treatment of SN is mainly targeted at the underlying disease<sup>19</sup>.

Post-steroid panniculitis occurs due to high doses of this drug, through systemic route, either oral or intravenous, followed by rapid withdrawal of the medication. Nodules appear one to ten days after the corticosteroids administration stopped. The histopathological findings may be identical to those of SCFN<sup>2</sup>.

Cold panniculitis occurs 48 to 72 hours after exposure to very low temperatures. The tissue sections show mostly lobular panniculitis with lymphocytes and histiocytes infiltrate, and superficial and deep dermal perivascular infiltrate without vasculitis<sup>2</sup>.

## Conclusions

SCFN is a pathology that, if it does not present complications, is benign and self-limiting, with no need for treatment. It is important to monitor NBs with special attention to hypercalcemia. Regular measure of serum calcium is recommended until the age of 6 months. Prospective studies would determine the prevalence and incidence of SCFN complications.

## Ethical Responsibilities

**Human Beings and animals protection:** Disclosure the authors state that the procedures were followed according to the Declaration of Helsinki and the World Medical Association regarding human experimentation developed for the medical community.

**Data confidentiality:** The authors state that they have followed the protocols of their Center and Local regulations on the publication of patient data.

**Rights to privacy and informed consent:** The authors have obtained the informed consent of the parents (tutors) of the patients and/or subjects referred to in the article. This document is in the possession of the correspondence author.

## Conflicts of Interest

Authors declare no conflict of interest regarding the present study.

## Financial Disclosure

Authors state that no economic support has been associated with the present study.

## References

1. Blázquez M, Revenga M, Llop M. Protocolo diagnóstico de las paniculitis. *Medicine* 2017;12:1599-603.
2. Polcari I, Stein S. Panniculitis in childhood. *Dermatologic Therapy* 2010 [cited 2019;23:356-67].
3. Borgia F, De Pasquale L, Cacace C, Meo P, Guarneri C, Cannavo SP. Subcutaneous fat necrosis of the newborn: be aware of hypercalcaemia. *J Paediatr Child Health* 2006; 42:316-8.
4. Del Pozzo-Magaña B, Ho N. Subcutaneous Fat Necrosis of the Newborn: A 20-Year Retrospective Study. *Pediatr Dermatol* 2016;33:e353-5.
5. Hogeling M, Meddles K, Berk D, et al. Extensive subcutaneous fat necrosis of the newborn associated with therapeutic hypothermia. *Pediatr Dermatol*. 2012;29:59-63.
6. Thomas JM, Bhandari J, Rytina E, Gass JK, Williams RM, Burrows NP. Subcutaneous Fat Necrosis of the Neonate with a Delayed Second Eruption. *Pediatr Dermatol* 2016;33:e134-6.
7. Rubin G, Spagnut G, Morandi F, Valerio E, Cutrone M. Subcutaneous fat necrosis of the newborn. *Clinical Case Reports* 2015;3:1017-20.
8. Mahé E, De Prost Y. Subcutaneous fat necrosis of the newborn. *Ann Dermatol Venerol* 2007; 134:494-8.
9. Kruse K, Irle U, Uhlig R. Elevated 1,25-dihydroxyvitamin D serum concentrations in infants with subcutaneous fat necrosis. *J Pediatr* 1993;122:460-3.
10. Shumer D, Thaker V, Taylor G, Wassner AJ. Severe hypercalcaemia due to subcutaneous fat necrosis: presentation, management and complications. *Arch Dis Child Fetal Neonatal* 2014; 99:19-21.
11. Vayú E, Rodríguez C, Wortsman X, Corredoira Y, Serman D, Strauch G. et al. Necrosis grasa del recién nacido: A propósito de un caso. *Rev Chil Pediatr* 2009;80:60-4.
12. Mahé E, Girszyn N, Hadj-Rabia S, Bodemer C, Hamel-Teillac D, De Prost Y. Subcutaneous fat necrosis of the newborn: a systematic evaluation of risk factors, clinical manifestations, complications and outcome of 16 children. *Br J Dermatol* 2007;156:709-15.
13. Beuzebec G, Aillet S, Bertheuil N, Delliere V, Thienot S, Watier E. Surgical management of subcutaneous fat necrosis of the newborn required due to a lack of improvement: a very rare case. *Br J Dermatol* 2014;171:183-5.
14. Akin M, Akin L, Coban D, Akcakus M, Balkanli S, Kurtoglu S. Post-operative subcutaneous fat necrosis in a newborn: a case report. *Fetal Pediatr Pathol* 2011;30:363-9.
15. Torrelo A, Hernández A. Panniculitis in Children. *Dermatol Clin* 2008; 26:491-500.
16. Hunt R. Subcutaneous fat necrosis of the newborn. In: Levy M, Corona R, editors. *UptoDate*. 2019; Jan 05.
17. Lara L, Villa A, Otero M, Akcakus M, Balkanli S, Kurtoglu S. Subcutaneous Fat Necrosis of the Newborn: Report of Five Cases. *Pediatrics and Neonatology* 2017;58:85-8.
18. Nair S, Nair S, Borade A, Ramakrishnan K. Hypercalcemia and metastatic calcification in a neonate with subcutaneous fat necrosis. *Indian J Pediatr* 2009;76:1155-7.
19. Weedon D. Chapter 17, Panniculitis en Weedon's Skin Pathology London: Churchill Livingstone Elsevier; 2016. p. 532-55.